



Correspondence

To the Editor,

I read with interest the article “Hypospadias: anatomy, etiology, and technique” by L Baskin and MB Ebberts [1]. I need to inform you that the method mentioned there—tubularized incised plate repair, also known as the Snodgrass procedure, was originally reported by me in detail in *Urologia Polska (Polish Urology)* in 1987 [2] and presented internationally in Vienna in 1989 [3]. Late results have been reported recently [4]. In addition, an informal story about the method has been presented recently [5]. The authors rightly describe the technique as a revolution which had long been ignored, as I feel it now, partly because it appeared too versatile, too easy to learn, and too revolutionary. The evolution of my studies into how wide a urethra we should reconstruct in order to further standardize hypospadias repair, with suggestions of a new hypospadias classification, is accessible online [6].

Yours sincerely,

Marek Orkiszewski
*Department of Pediatric Surgery and Traumatology
 Collegium Medicum, Nicolaus Copernicus University
 Torun Crezna 5, 60-289 Poznan, Poland
 E-mail address: marek.orkiszewski@gmail.com*

doi:10.1016/j.jpedsurg.2006.07.005

References

- [1] Baskin LS, Ebberts MB. Hypospadias: anatomy, etiology and technique. *J Pediatr Surg* 2006;41:263-2006.
- [2] Orkiszewski M. Urethral reconstruction in skin deficit. *Urol Pol/Polish Urology* 1987;40:12-5.
- [3] Orkiszewski M: A longitudinal split-thickness to widen the Byars skin flap as alternative to extragenital skin graft in hypospadias repair. XV gemeinsame Tagung der Oesterreichischen Gesellschaft fuer Urologie und Bayerischen Urologenvereinigung, Vienna June 1-3, 1989.
- [4] Orkiszewski M, Leszniewski J. Morphology and urodynamics after longitudinal urethral plate incision in proximal hypospadias repairs: long-term results. *Eur J Pediatr Surg* 2004;14:35-8.
- [5] Orkiszewski M. Letter to the editor. *Pediatr Surg Int* 2006;32:302.
- [6] Orkiszewski M, Madej J, Kilian T. How wide a urethra should we produce? *J Pediatr Urol* 2006 (in press).

Reply to letter to the editor

Dear Dr. Orkiszewski,

I read with interest your letter to the editor concerning our article on hypospadias (*J Pediatr Surg*. 2006;41:463). I appreciate the chance to review your description of your procedure for redo hypospadias titled “Urethral reconstruction in skin deficit,” published in *Urologia Polska [Polish Urology]* 1987;40:12-15. I have taken the liberty of republishing Fig. 1 from this article, reinforcing the idiom that a picture is worth a thousand words. Congratulations on your outstanding contribution to hypospadias reconstruction, which has proven to be successful for not only redo hypospadias but also for primary urethral reconstruction. In the future, I encourage you to publish your data in journals that are accessible via Medline so that all hypospadiologists and their patients may benefit.

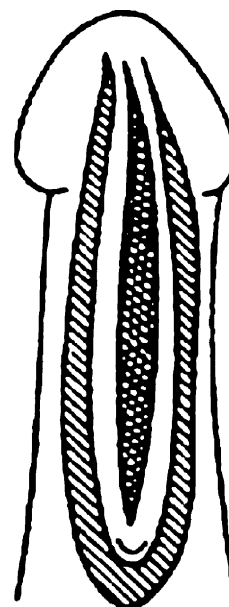


Fig. 1 Primary tubularization with incision of urethral place. Reprinted with permission from *Urologia Polska*. 1987;40:12-15.

Laurence Baskin
*UCSF Childrens Hospital
 San Francisco CA 94143, USA
 E-mail address: lbaskin@urology.ucsf.edu*

doi:10.1016/j.jpedsurg.2006.07.006